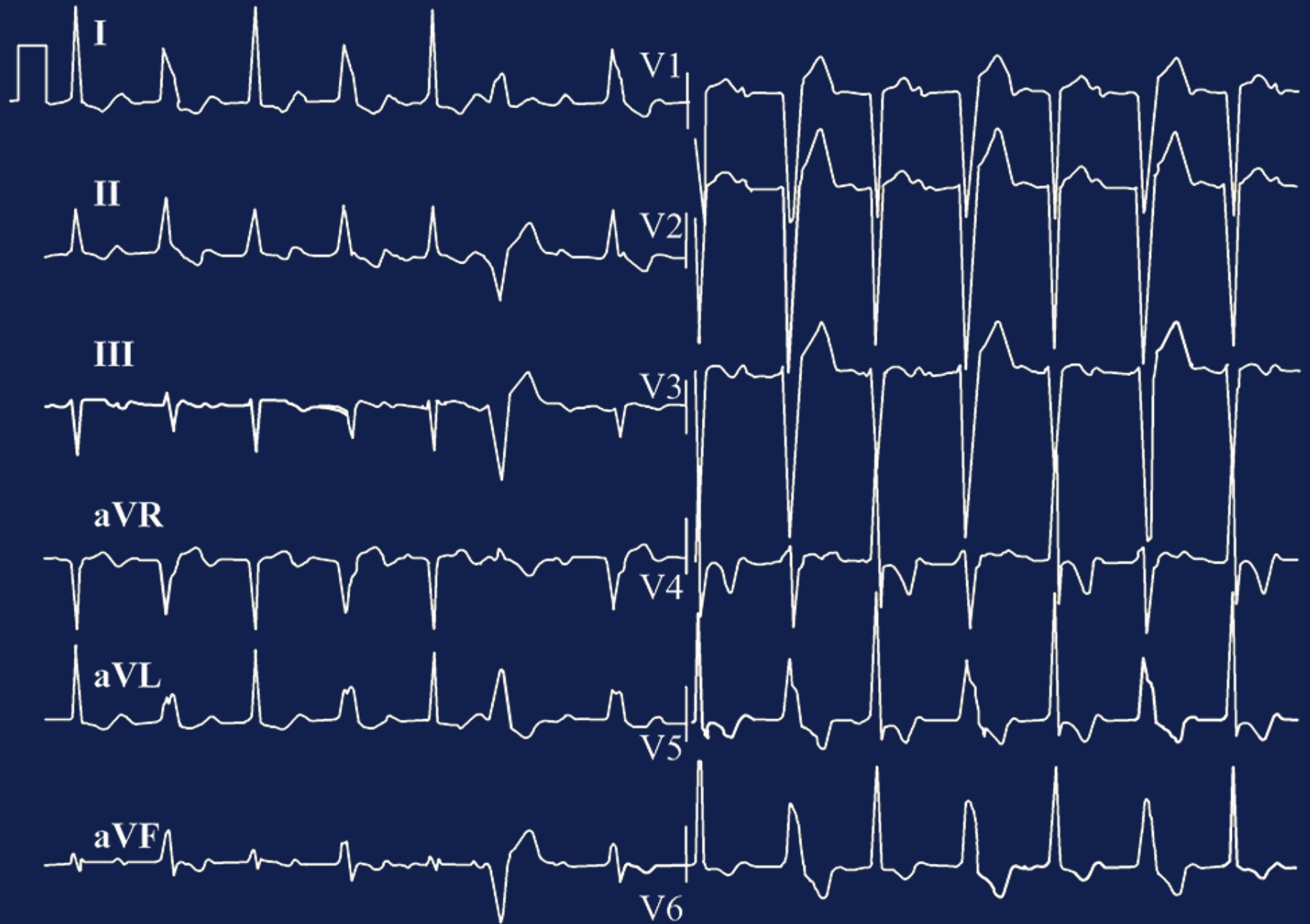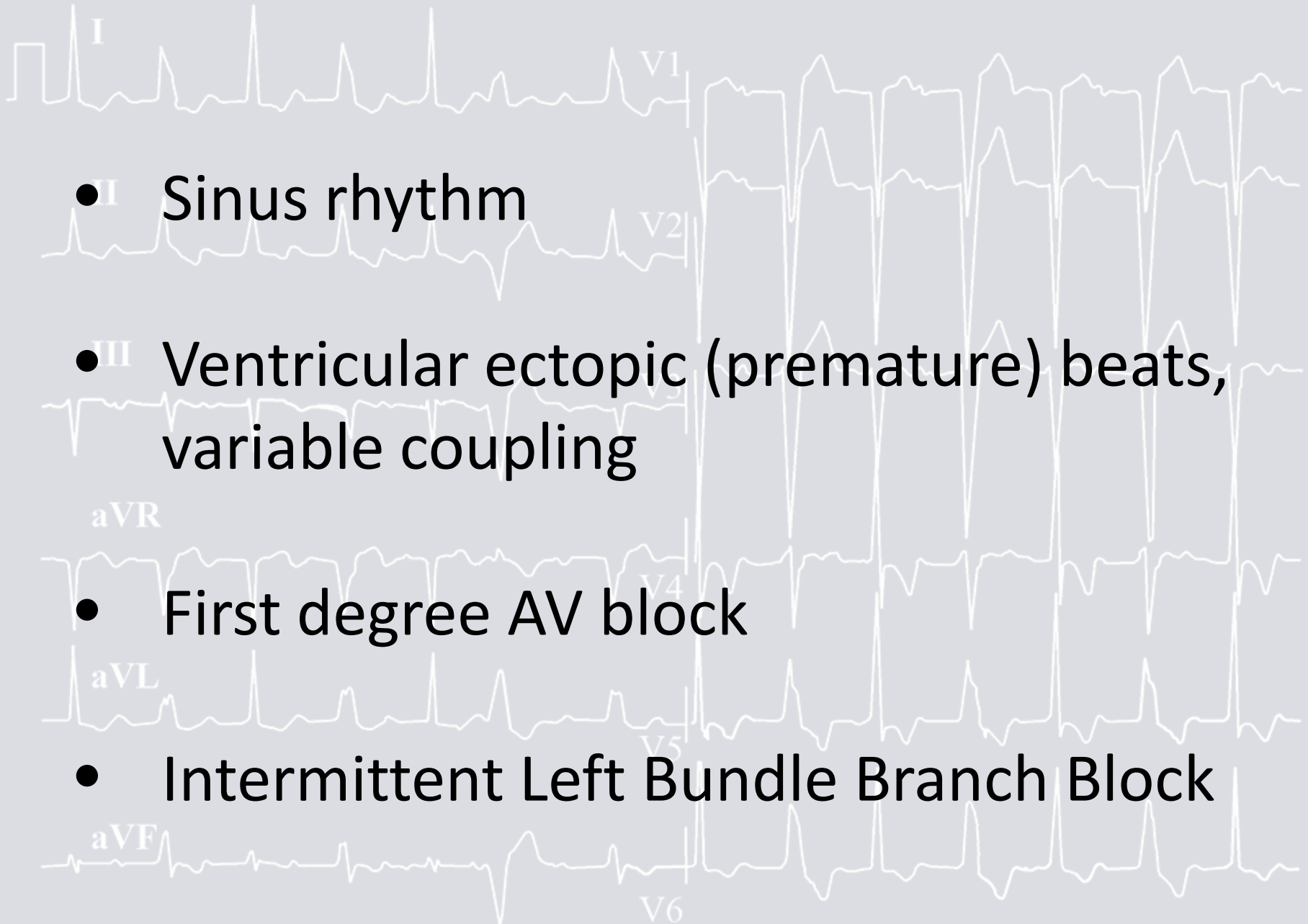


FIRST ECG – DAY 1



FIRST ECG – DAY 1



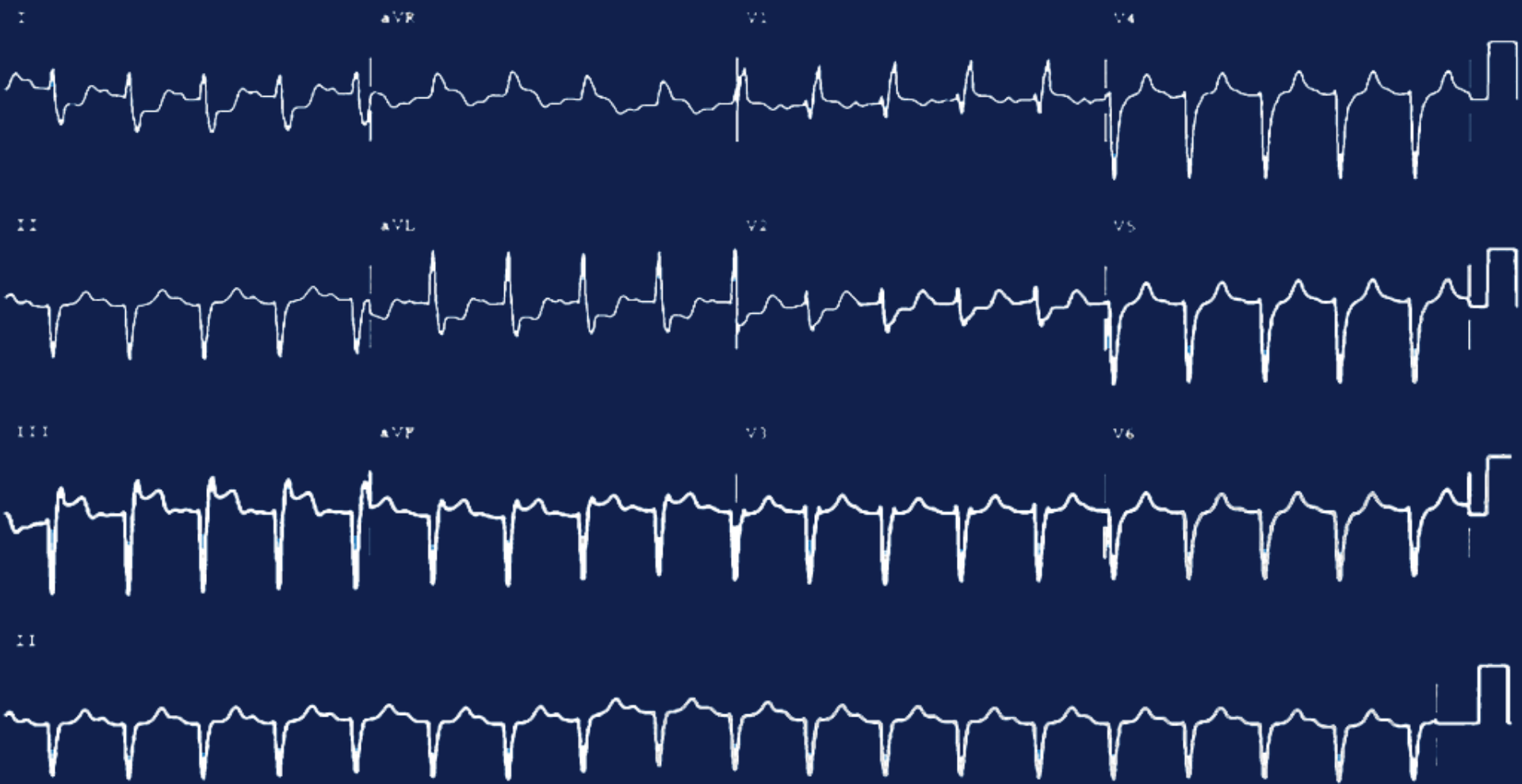- **I** Sinus rhythm

- **III** Ventricular ectopic (premature) beats, variable coupling

- First degree AV block

- Intermittent Left Bundle Branch Block

FIRST ECG – DAY 2



FIRST ECG – DAY 2

- Sinus tachycardia



- Right Bundle Branch Block (RBBB)



- Left anterior fascicular block



- Myocardial Infarction (STEMI), inferior wall

